

Solutions



How to make an overdenture easily ?

- ✿ Use a temporary denture as a guide for
 - ✱ a final denture
 - ✱ a surgical stent
 - ✱ a customized final impression tray

“ Temporary denture should be made carefully “

Use a temporary denture as a guide for a final denture

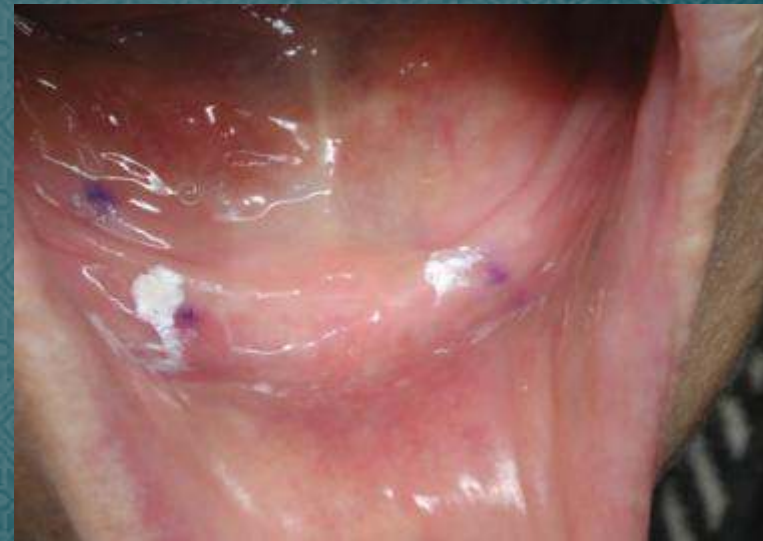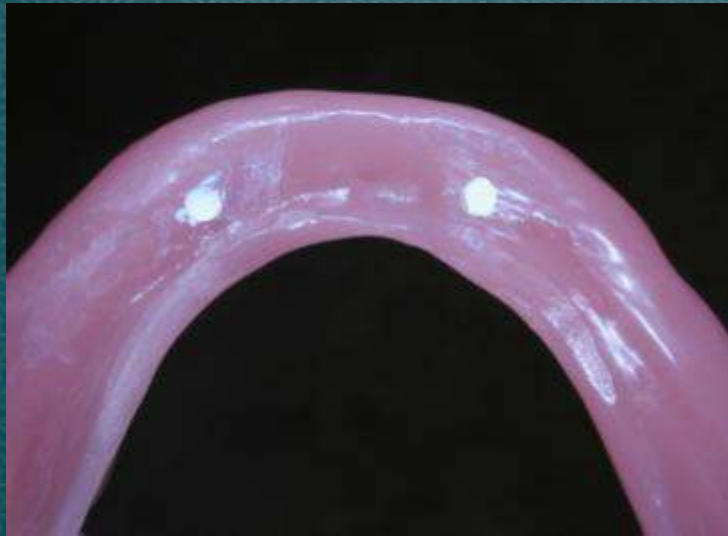
✿ facial harmony

- * protruded or retruded
- * vertical dimension
- * tooth shade

So, temporary denture should be made as good as possible 😊

A surgical stent

- ✿ CT or PANO with a temporary denture
 - * use directly or clear stent during surgery



ZOE or stopping can be used

A customized final impression tray

- ✿ With soft relining material
 - ✿ Viscogel
 - ✿ Coe soft
 - ✿ Tissue conditioner etc.

Total treatment procedure for an overdenture

✿ Diagnosis

- ✱ Oral exam, X-ray & study model
- ✱ Decision making for an prosthesis
 - ✱ Fixed type or overdenture
 - ✱ How many and where to place implants

✿ Temporary denture state

- ✱ extraction & healing period
- ✱ Implants placement with a surgical stent
- ✱ double check the treatment plan

✿ Final prosthesis

- ✿ a final impression with attachments in situ
- ✿ denture frame over attachments
- ✿ wax rim, esthetic try in with the reference of a temporary denture
- ✿ a final denture without attachment plastic
- ✿ plastic insertion after 3~4 weeks later

✿ Maintenance

- ✱ If implant retained overdenture, check the denture stability for relining
(about 2~3 years later depending on the pt.)

** Post. bone resorption is 2~3 times faster than in a complete denture wearer. ***

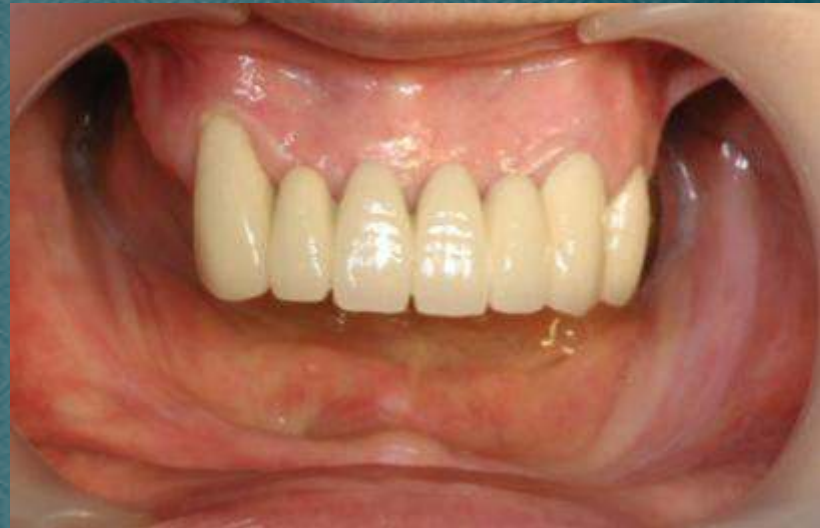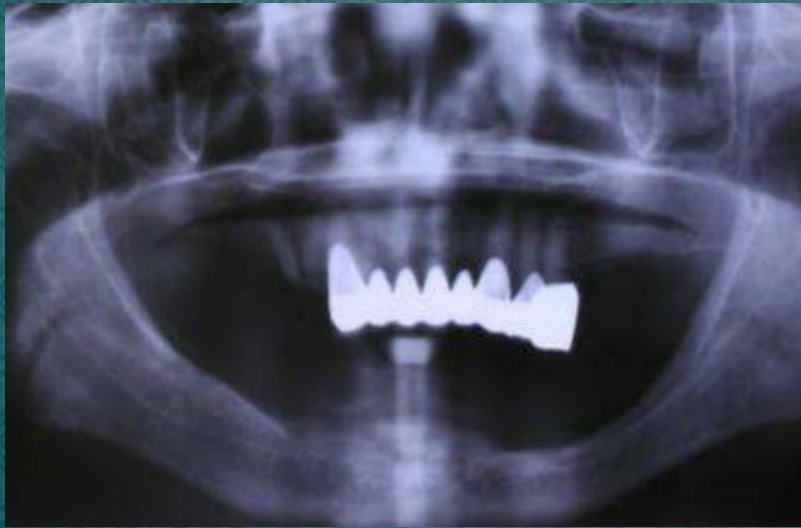Considerations during check up

- ✿ Food impacts into the denture than before.
- ✿ The denture is moving up & down than before
- ✿ Always check the stability of the denture.

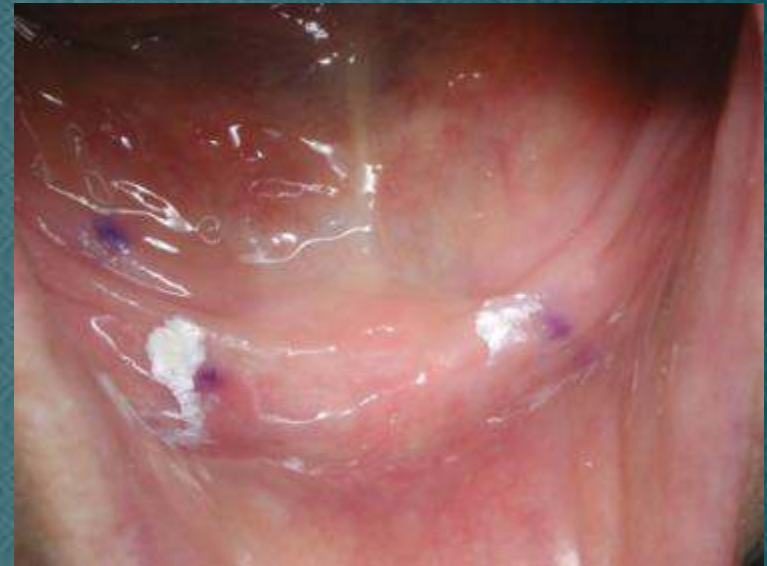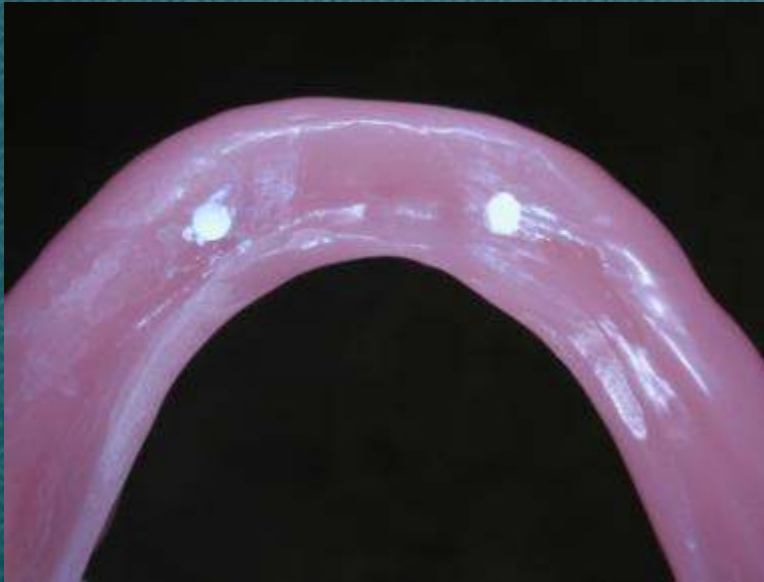


If it is unstable, adverse stress can be applied to the implants even though the patient is unaware of it, so think of relining during check-up

Case

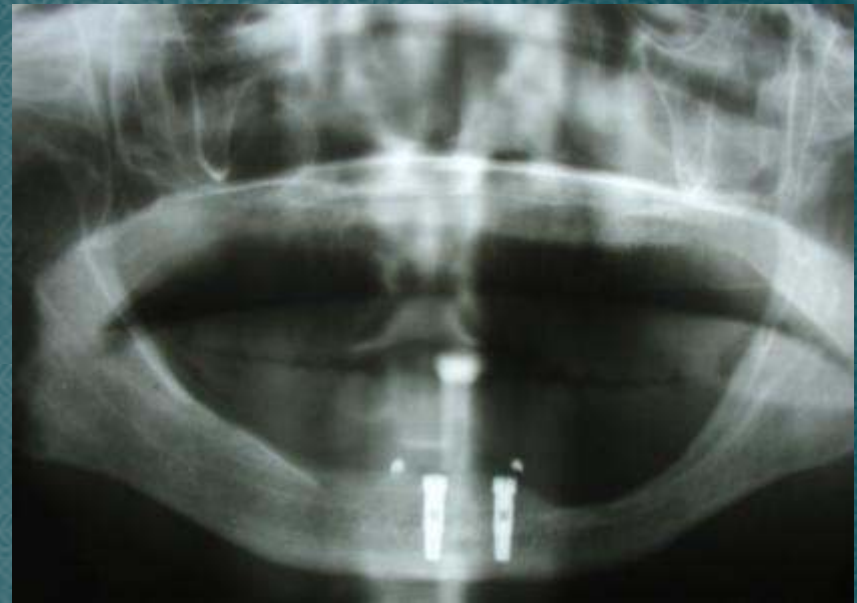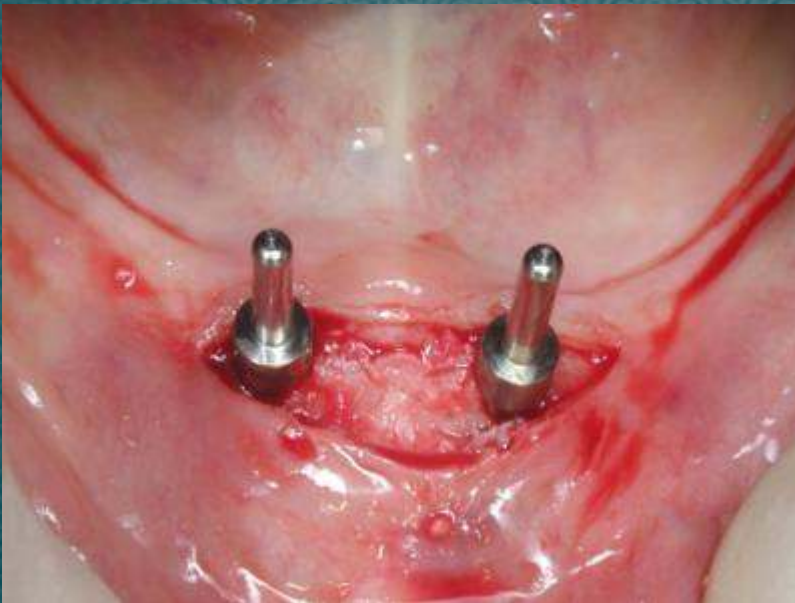


03 12 16



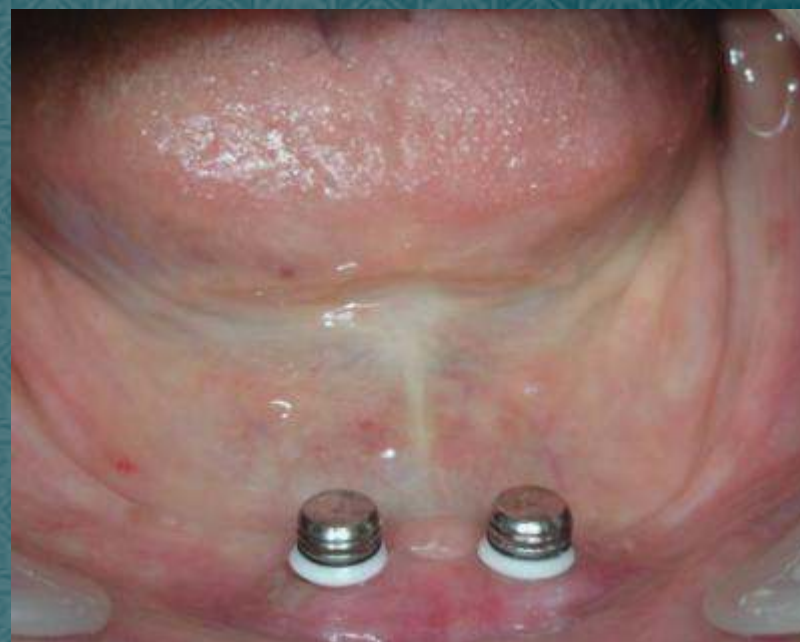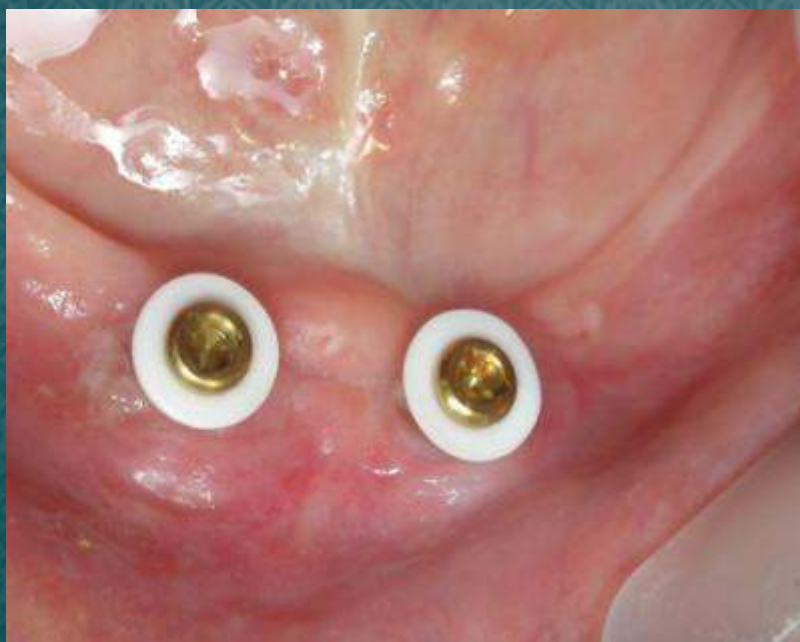04 02 05

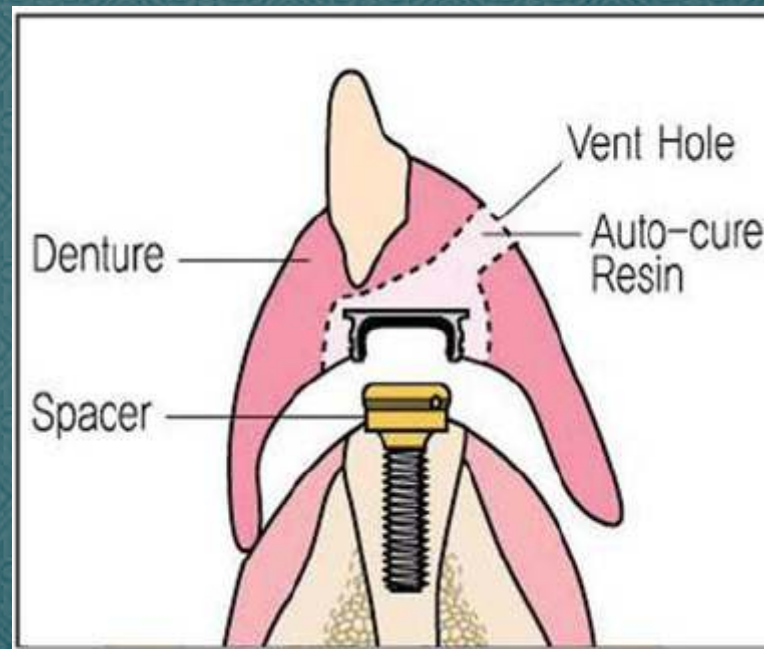
Using a permanent denture,
marking with ZOE was done & taking a X-ray

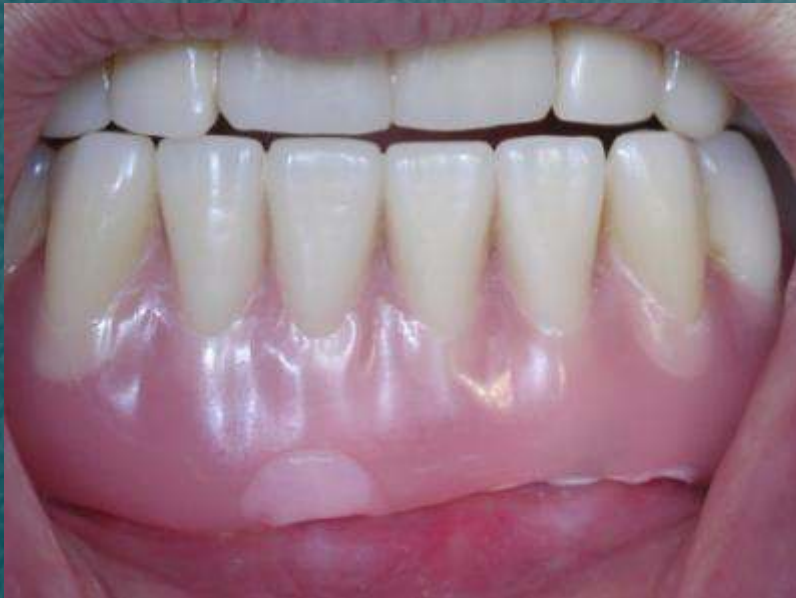

04 02 06

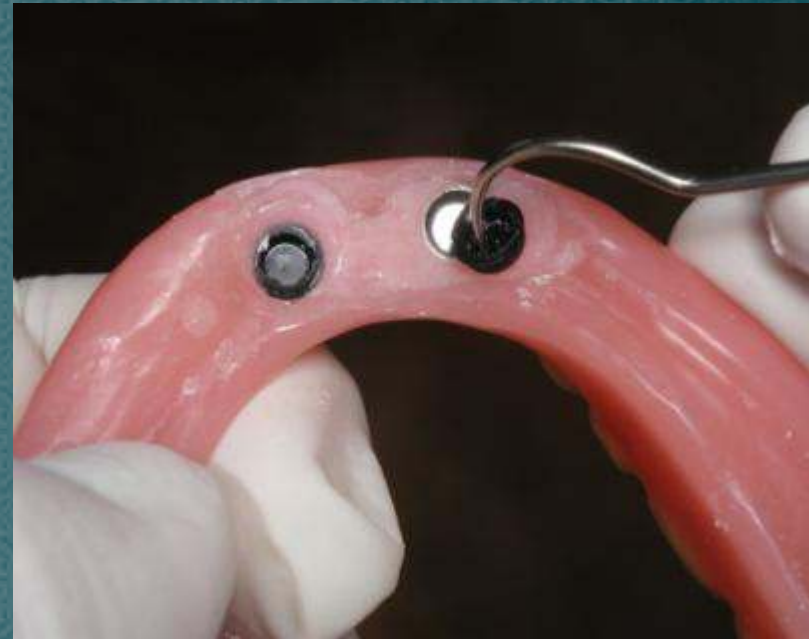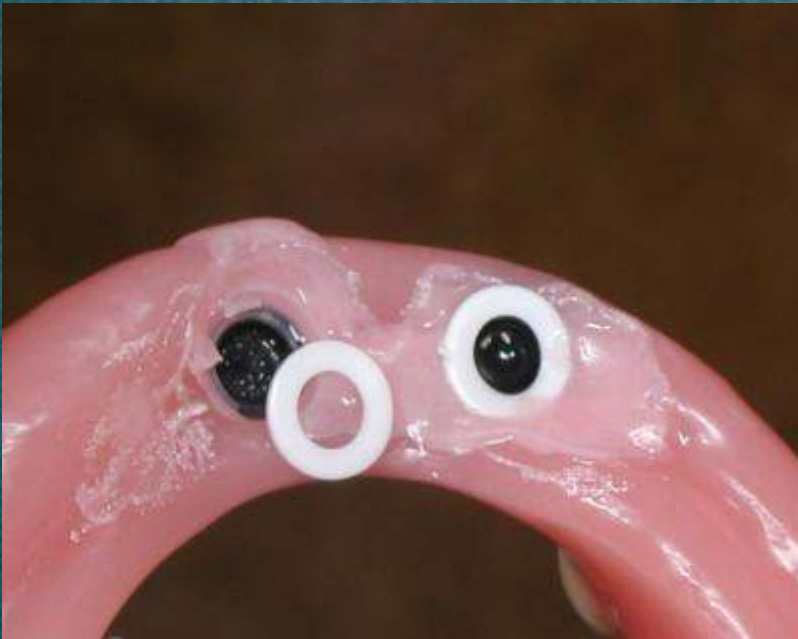Implants were placed more frontally
placed than expected.



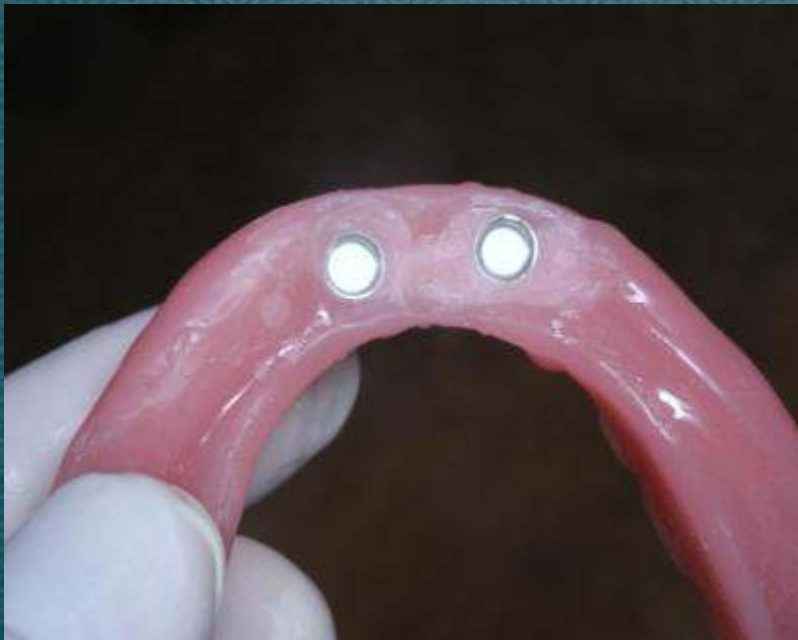



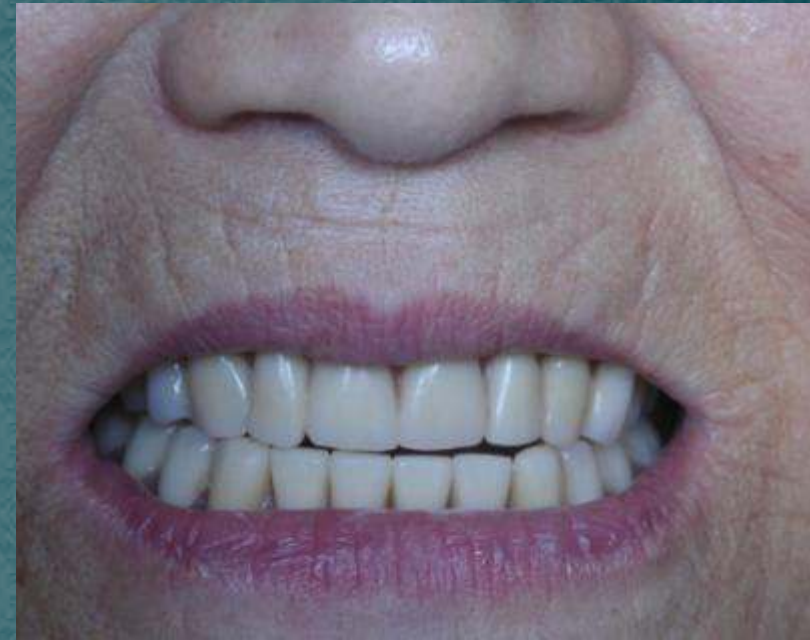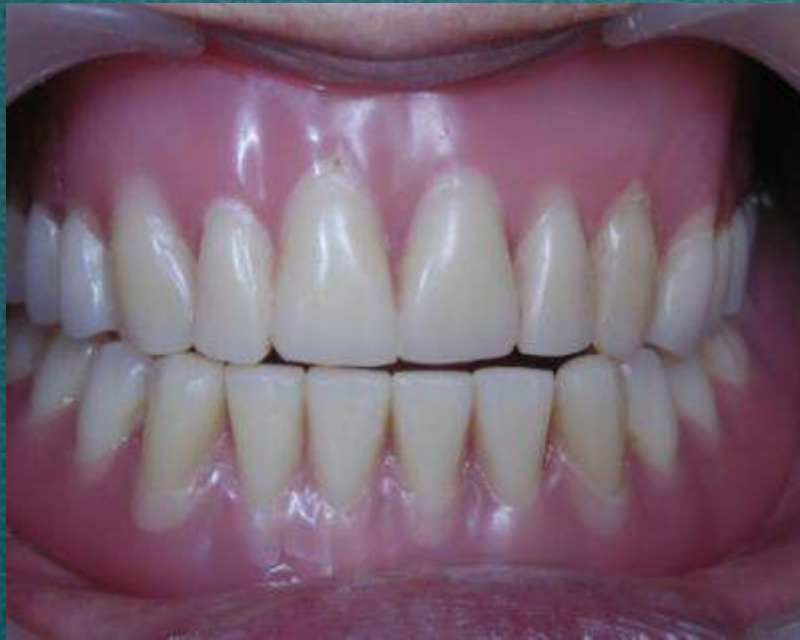Because of the final denture being used for a healing period with implant area relieved, male plastic inserts could be attached on site.



Carefully remove any debris in & around the mental housing.

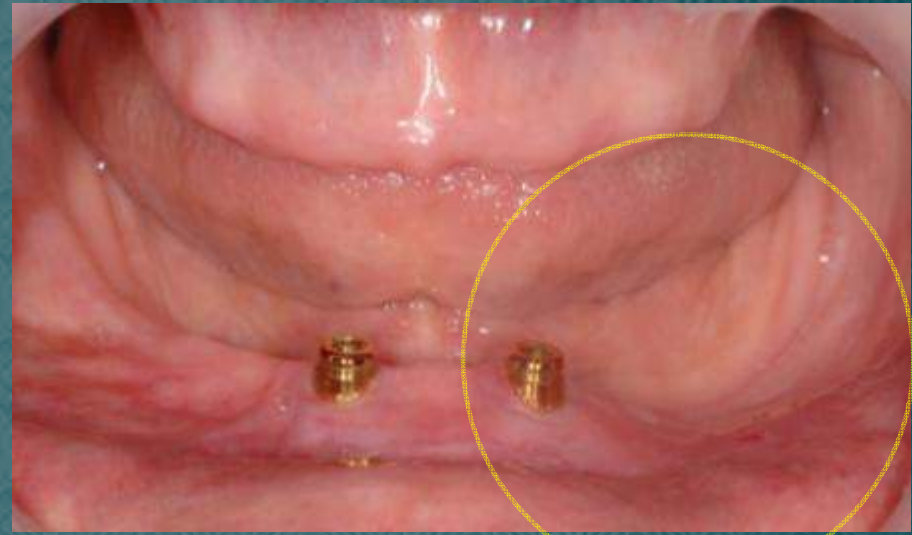
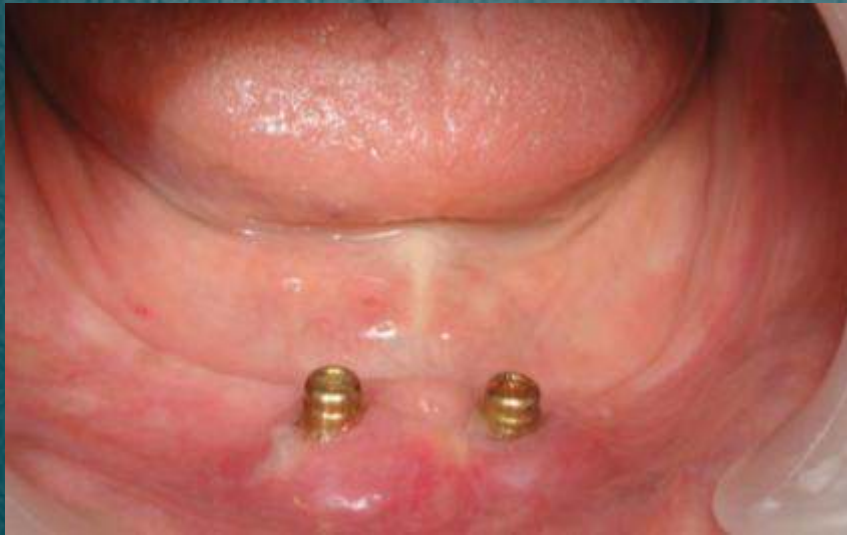

Replace with pink plastic males (3 lb).

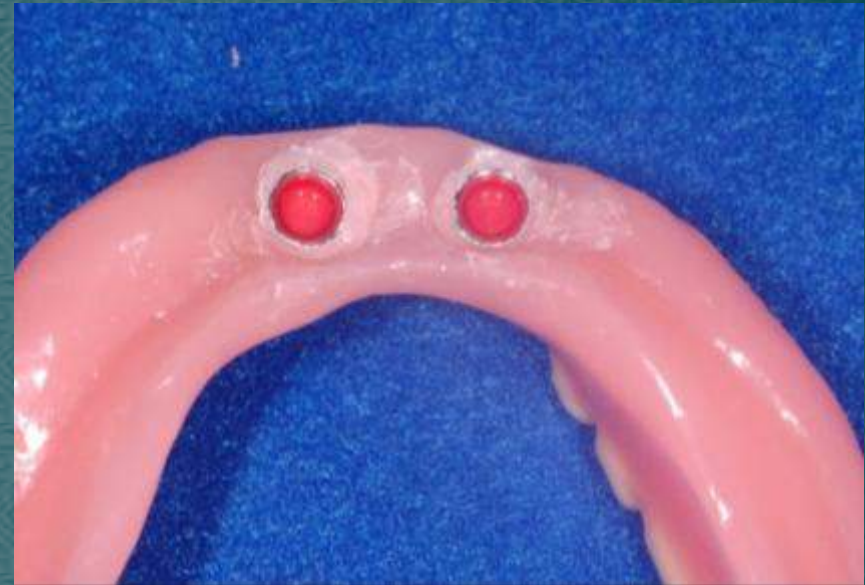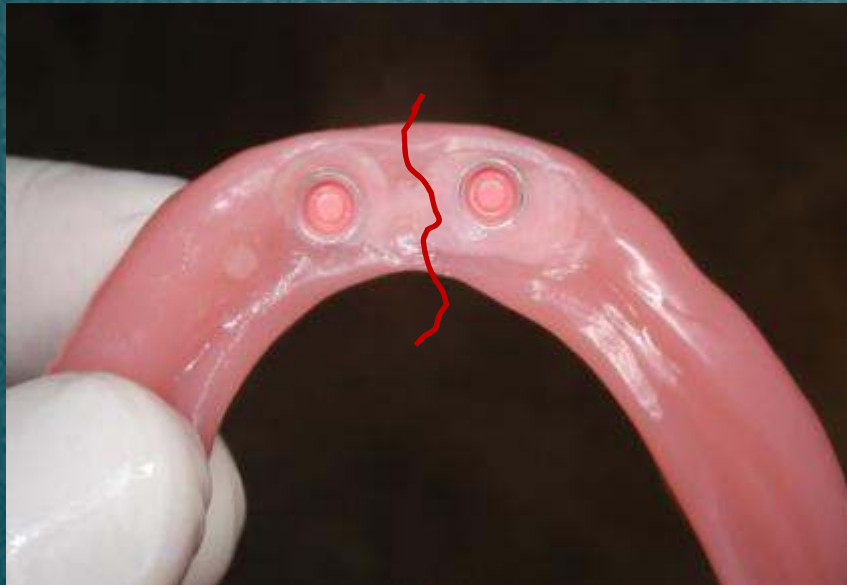


04 05 21

Maintenance



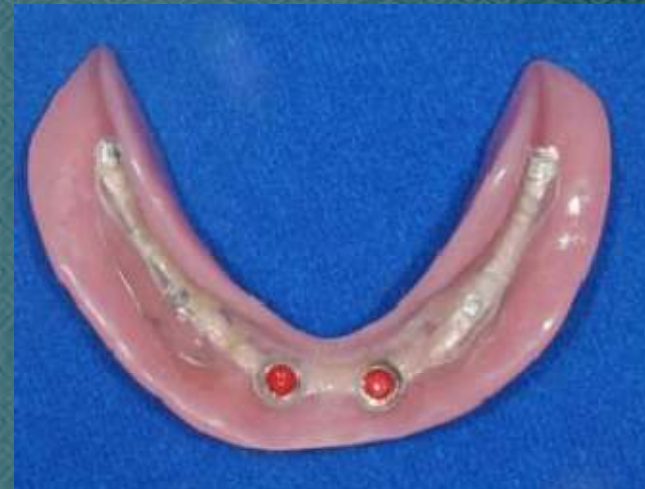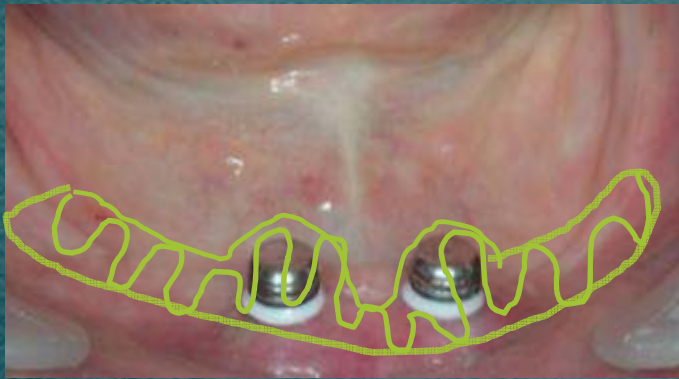2 years later after denture delivery



In fact, the denture was in a cracked state.
So, relining of the denture (sent to the lab.) and reattachment
of male plastics were done in the dental office.

How to prevent crack?

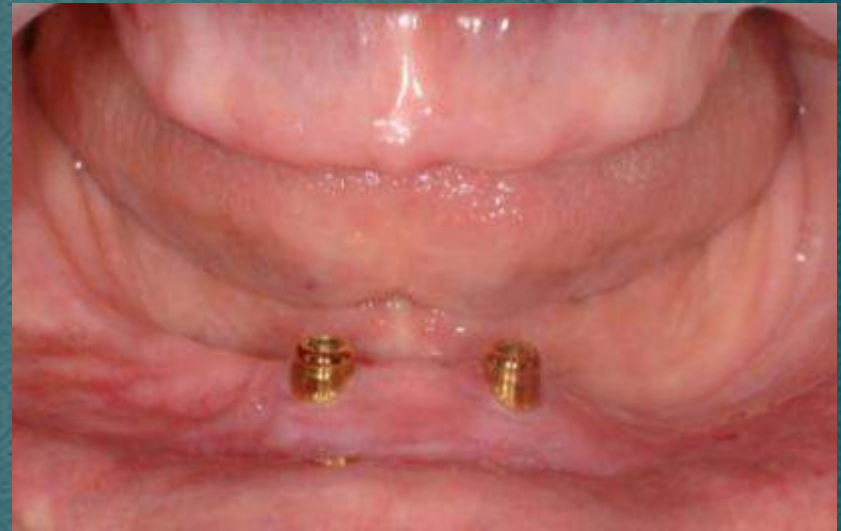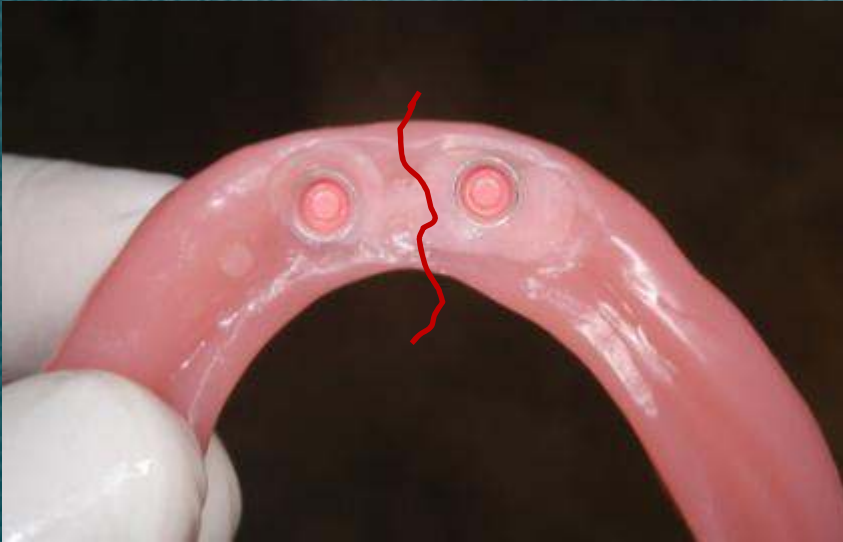
- ✿ Metal frame reinforcement over the mental housing is important



For making a room for the denture, metal housing should be in situ during taking a final impression

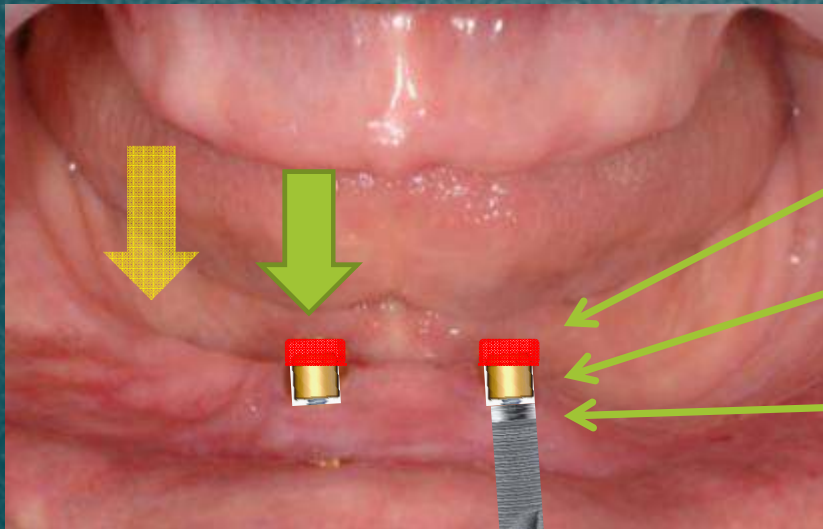
.....

✿ Even though there seems to be a bulky denture, it can be cracked.



Where is the force ?

.....



Easily broken or pop-out

Easily worn-down than the other

More Marginal bone loss

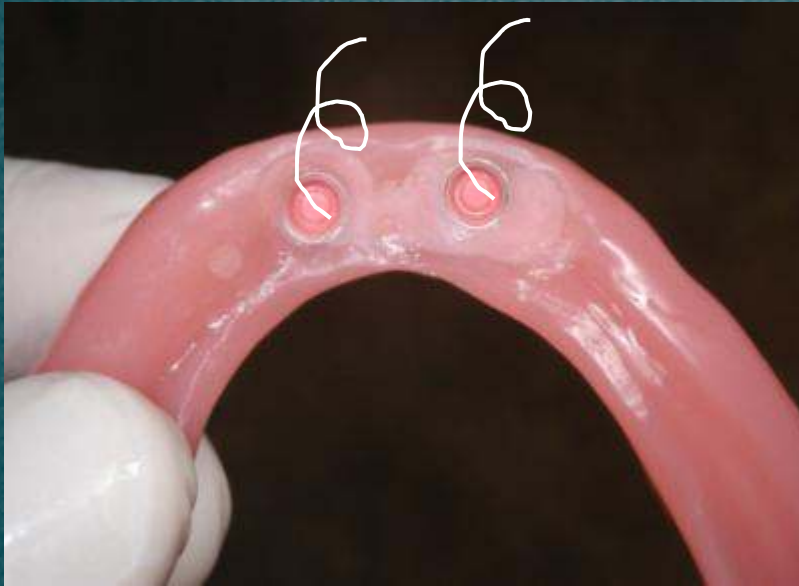


If connecting the abutment directly without using a denture for a period of time, or if not relined properly

When to reline

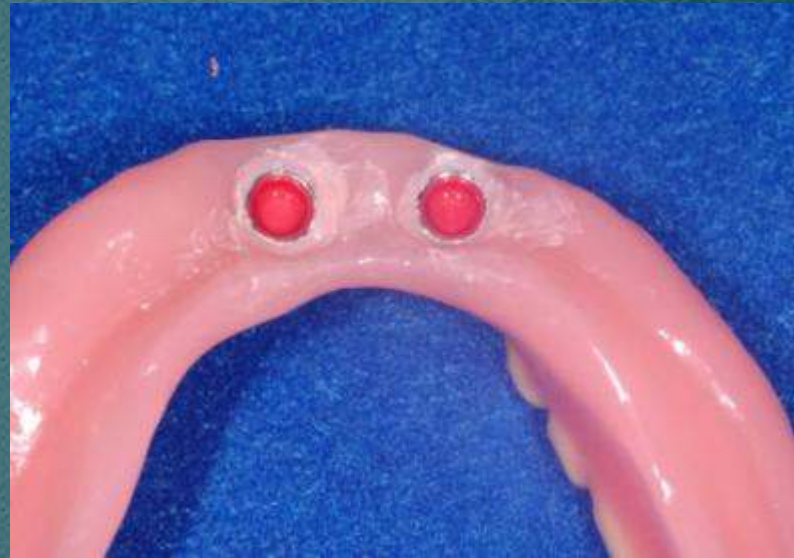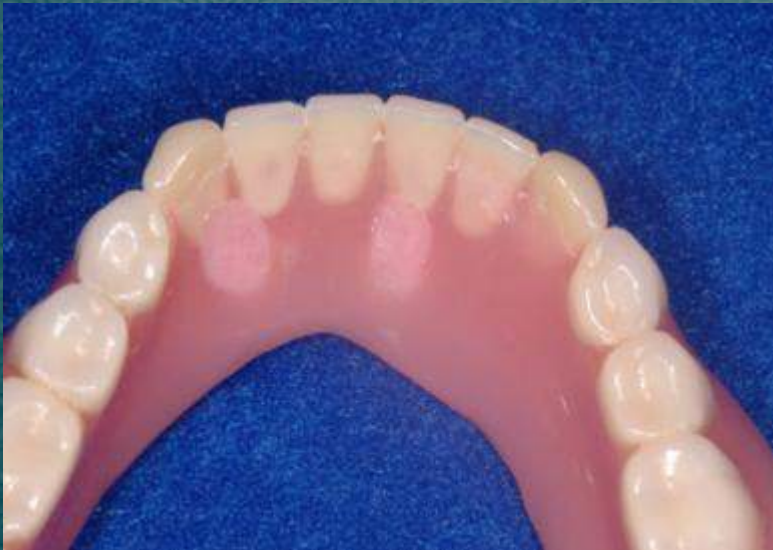- ✱ Food impaction ↑
- ✱ Denture movement ↑
- ✱ Denture cracks

How to reline?



- ✿ Remove the metal housing in the denture carefully
- ✿ Relining the denture with soft reliner & send it to the lab. (Indirect method)

.....
✿ Attach the caps to the denture in the mouth as before (Direct method)



.....

✿ If a resin denture is expected to be fractured in the future,
please make a comment to the Lab. to reinforce the resin base with metal frame.